

## Complete percutaneous treatment of vertebral body tumors causing spinal canal compromise using a transpedicular cavitation, cement augmentation, and radiosurgical technique

PETER C. GERSZTEN, M.D., M.P.H., AND EDWARD A. MONACO III, M.D., PH.D.

*Departments of Neurological Surgery and Radiation Oncology, University of Pittsburgh Medical Center, Pittsburgh, Pennsylvania*

**Object.** Patients with symptomatic pathological compression fractures require spinal stabilization surgery for mechanical back pain control and radiation therapy for the underlying malignant process. Spinal radiosurgery provides excellent long-term radiographic control for vertebral metastases. Percutaneous cement augmentation using polymethylmethacrylate (PMMA) may be contraindicated in lesions with spinal canal compromise due to the risk of displacement of tumor resulting in spinal cord or cauda equina injury. However, there is also significant morbidity associated with open corpectomy procedures in patients with metastatic cancer, especially in those who subsequently require adjuvant radiotherapy. This study evaluated a treatment paradigm for malignant vertebral compression fractures consisting of transpedicular coblation corpectomy combined with closed fracture reduction and fixation, followed by spinal radiosurgery.

**Methods.** Eleven patients (6 men and 5 women, mean age 58 years) with symptomatic vertebral body metastatic tumors associated with moderate spinal canal compromise were included in this study (8 thoracic levels, 3 lumbar levels). Primary histologies included 4 lung, 2 breast, 2 renal, and 1 each of thyroid, bladder, and hepatocellular carcinomas. All patients underwent percutaneous transpedicular coblation corpectomy immediately followed by balloon kyphoplasty through the same 8-gauge cannula under fluoroscopic guidance. Patients subsequently underwent radiosurgery to the affected vertebral body (mean time to treatment 14 days). Postoperatively, patients were assessed for pain reduction and neurological morbidity.

**Results.** There were no complications associated with any part of the procedure. Adequate cement augmentation within the vertebral body was achieved in all cases. The mean radiosurgical tumor dose was 19 Gy covering the entire vertebral body. The procedure provided long-term pain improvement and radiographic tumor control in all patients (follow-up range 7–44 months). No patient later required open surgery. No radiation-induced toxicity or new neurological deficit occurred during the follow-up period.

**Conclusions.** This treatment paradigm for pathological fractures of percutaneous transpedicular corpectomy combined with cement augmentation followed by radiosurgery was found to be safe and clinically effective. This technique combines minimally invasive procedures that avoid the morbidity associated with open surgery while providing spinal canal decompression and immediate fracture stabilization, and then administering a single-fraction tumoricidal radiation dose. (DOI: 10.3171/2009.9.FOCUS09184)

**KEY WORDS** • **compression fracture** • **kyphoplasty** • **metastasis** • **minimally invasive surgery** • **stereotactic radiosurgery** • **spine tumors**

**T**HERE has been an evolution over the past decade of minimally invasive surgical techniques applied to the field of spine surgery.<sup>32</sup> Such techniques follow a natural trend in surgery to minimize the injury to normal tissue while obtaining the same or better surgical outcome than invasive techniques. In a similar fashion, there has been significant interest in applying minimally invasive techniques to the field of spine oncology. By joining modern medical technology with traditional spinal approaches, the classical goals of open spinal surgery

can now be effectively and reproducibly accomplished through much smaller corridors and with far less iatrogenic damage to the vital dorsal musculoligamentous complex.<sup>16,33,46</sup>

Patients with metastatic spine tumors are often debilitated and at a high risk for surgical morbidity. For patients with limited life expectancies from their underlying disease, high surgical complication rates with subsequent decrease in quality of life are most unacceptable.<sup>49,50</sup> It is for these reasons that minimally invasive techniques have been explored with great enthusiasm for the treatment of spine tumors. This trend has been led by the realization that open surgeries for spinal metastases are associated

*Abbreviation used in this paper:* PMMA = polymethylmethacrylate.

with significant morbidity and a high complication rate in this already debilitated patient population.<sup>3,26,31,39,49–51</sup>

As part of this trend, there has been a steady increase in the past decade in the use of percutaneous vertebral body injection of PMMA for the treatment of symptomatic cancer-associated compression fractures. Recent publications have demonstrated a significant improvement in clinical outcomes, including pain, using both the vertebroplasty<sup>11,17,52</sup> as well as the kyphoplasty techniques.<sup>15,17,30</sup> Several publications have specifically addressed vertebroplasty and kyphoplasty for pathological fractures.<sup>12,15,17,18,22,30,36,48</sup> Injection of PMMA into the involved vertebral body allows for immediate stabilization of the fracture and thus pain improvement.

There are several limitations of the kyphoplasty procedure for pathological compression fractures.<sup>15,17,30</sup> Because no tumor is removed at the time of the kyphoplasty procedure, there is a risk that the tumor will be pushed posteriorly into the spinal canal during balloon inflation. Furthermore, during balloon inflation, the tumor in the middle of the vertebral body is being displaced toward the fractured cortical bone. Therefore, during placement of the PMMA, there remains a “rim” of tumor between the PMMA and the cortical bone. The PMMA is prevented from direct contact and thus support of the fractured vertebral body endplate. This limitation could lead to suboptimal biomechanical stability and thus, less than ideal clinical outcome. Recent technological advances have allowed for the capability to perform direct tumor removal via the kyphoplasty cannula, thus, decreasing the risk of these aforementioned complications.

Multiple studies have demonstrated the feasibility and clinical efficacy of spinal radiosurgery for both primary and secondary malignancies.<sup>1,2,4,8,13,38,41,42,47</sup> The utility of combining radiosurgery with percutaneous cement augmentation has been described.<sup>22</sup> In patients with pain secondary to pathological compression fractures associated with minimal to moderate spinal canal compromise, combining a percutaneous cytorreduction and kyphoplasty fracture fixation procedure followed by spinal radiosurgery would allow for the immediate stabilization of the fracture as well as for the delivery of a tumoricidal dose to control local disease progression in patients who otherwise might not be candidates for the procedure. Both procedures are intended to help relieve the underlying pain associated with this condition, thereby improving the patient’s quality of life. The object of this study was to assess the safety and clinical efficacy of a new completely percutaneous treatment paradigm followed by spinal radiosurgery for the treatment of painful vertebral body compression fractures in patients with cancer.

## Methods

This study involved the prospective evaluation of 11 consecutive patients with pain secondary to pathological compression fractures from metastatic disease who underwent transpedicular coblation corpectomy combined with closed fracture reduction and fixation involving kyphoplasty (Kyphon Inc.), followed by spinal radiosurgery delivered using either the CyberKnife Image-Guid-

ed Radiosurgery System (Accuray, Inc.) or the Synergy S (Elekta, Inc.). The Elekta Synergy S 6-MV linear accelerator contains a beam modulator and cone beam image guidance combined with a robotic couch that allows positioning correction in 3 translational and 3 rotational directions. All patients were treated at the University of Pittsburgh Medical Center in Pittsburgh, Pennsylvania, and the protocol was approved by the institutional review board at the University of Pittsburgh.

The study cohort included 6 men and 5 women. Patient ages ranged from 38 to 87 years (mean 58 years). The primary cancer diagnoses included 4 lung, 2 breast, 2 renal, and 1 each of thyroid, bladder, and hepatocellular carcinomas. Eight lesions were in the thoracic spine and 3 in the lumbar spine. Eight lesions had received prior external beam irradiation with spinal cord tolerance doses that precluded any further conventional irradiation. The primary indication for treatment was pain in all cases. No patients had signs or symptoms of myelopathy or other neurological deficit at the time of surgery. All patients had known primary disease determined from another site prior to the procedure. The specific lesions treated had not been previously biopsied. All patients underwent MR imaging to assess the degree of spinal cord or cauda equina compromise prior to selection. Magnetic resonance imaging also assisted in the evaluation of the extent of involvement of the pedicles or of disease within the spinal canal. This information was used such that the radiosurgery contouring included this tumor within the treatment plan.

The cohort represented 11 consecutive patients who were referred for symptomatic spine metastases and who met the inclusion criteria. For inclusion in this series, patients must have demonstrated between 20 and 50% (“moderate”) spinal canal compromise at the level of disease and were not believed to be candidates for kyphoplasty alone. Patients with > 50% spinal canal compromise were believed not to be candidates for this procedure and were referred for open surgical decompression. The technique of combined percutaneous transpedicular tumor debulking and kyphoplasty for pathological compression fractures has been described.<sup>25</sup> The Cavity Spine Wand (ArthroCare Corp.) uses proprietary Coblation technology to volumetrically remove tissue using a radiofrequency plasma-mediated tissue dissolution process (Figs. 1 and 2). The device is capable of removing tissue with minimal thermal injury at the margin. The kyphoplasty technique using the KyphX balloon (Kyphon Inc.) was performed in all cases under general anesthesia as described elsewhere.<sup>15,17,28,34,54</sup> An 8-gauge introducer cannula was placed via a bilateral transpedicular approach targeting the center of the vertebral body. The 8-gauge Cavity SpineWand was then placed directly through the cannula, and the tumor was ablated in a circumferential manner under fluoroscopic guidance. The physically allowable arc for the working tip is 16°. The goal was to create a cavity within the effected vertebral body prior to balloon insertion. The created cavity space could be visualized on lateral fluoroscopic imaging. The exact volume of tumor removed by the wand cannot be measured. The cavity size was extrapolated by the different positions of

## Combined percutaneous corpectomy and radiosurgery technique

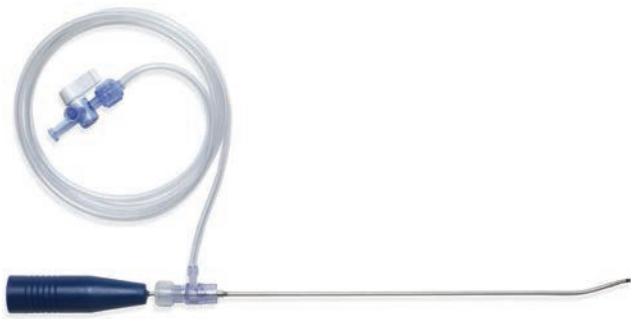


Fig. 1. Photograph showing the Cavity SpineWand with its curved end that allows for maximum tissue removal within the vertebral body.

the wand tip within the affected vertebral body. There were no complications associated with the procedure. Polymethylmethacrylate was then placed into the cavity under fluoroscopic visualization. There was no case of extravasation of PMMA into the spinal canal as determined by the radiosurgery CT simulation scan.

For those patients treated using the CyberKnife platform, after the kyphoplasty portion of the operation was completed, 4–5 gold fiducial markers (0.62 × 5 mm; Alpha/Omega Services) were implanted into the adjacent pedicles both rostral as well as caudal to the lesion using the same bilateral kyphoplasty stab incisions. This technique is described elsewhere.<sup>24</sup> Patients subsequently underwent a treatment-planning CT scan. The patients were placed supine in a conformal alpha cradle during CT imaging as well as during treatment. Computed tomography scans were acquired using 1.25-mm-thick slices to include the lesion of interest as well as all fiducials.<sup>23</sup>

For those patients treated using the Synergy S platform, patients were immobilized with the BodyFix system (total body bag; Medical Intelligence). The linear accelerator was also equipped with a HexaPOD couch (Medical Intelligence) that allowed patient positioning correction in 3 translational and 3 rotational directions. The Pinnacle treatment planning system (version 8.0; Philips) and a 1.5-mm CT slice thickness were used to plan the Synergy spinal radiosurgery treatments.

The entire vertebral body and any adjacent tumor extension were included within the radiosurgical treatment plan as the clinical target volume. Extravertebral extension of tumor also was targeted when clinically indicated. The patients then returned for the radiosurgical treatment to the lesion. All treatments were performed using a single fraction technique in an outpatient setting. For evaluation of pain relief, a 10-point verbal visual analog scale with intensity description was administered prior to the procedure, at 1 month, and until the last clinical follow-up.

### Results

All patients successfully completed the 2 procedures. There were no complications associated with any part of the procedure. Adequate cement augmentation within the vertebral body was achieved in all cases. Cement was retained within the limits of the vertebral body as determined by the radiosurgical CT simulation in all cases.

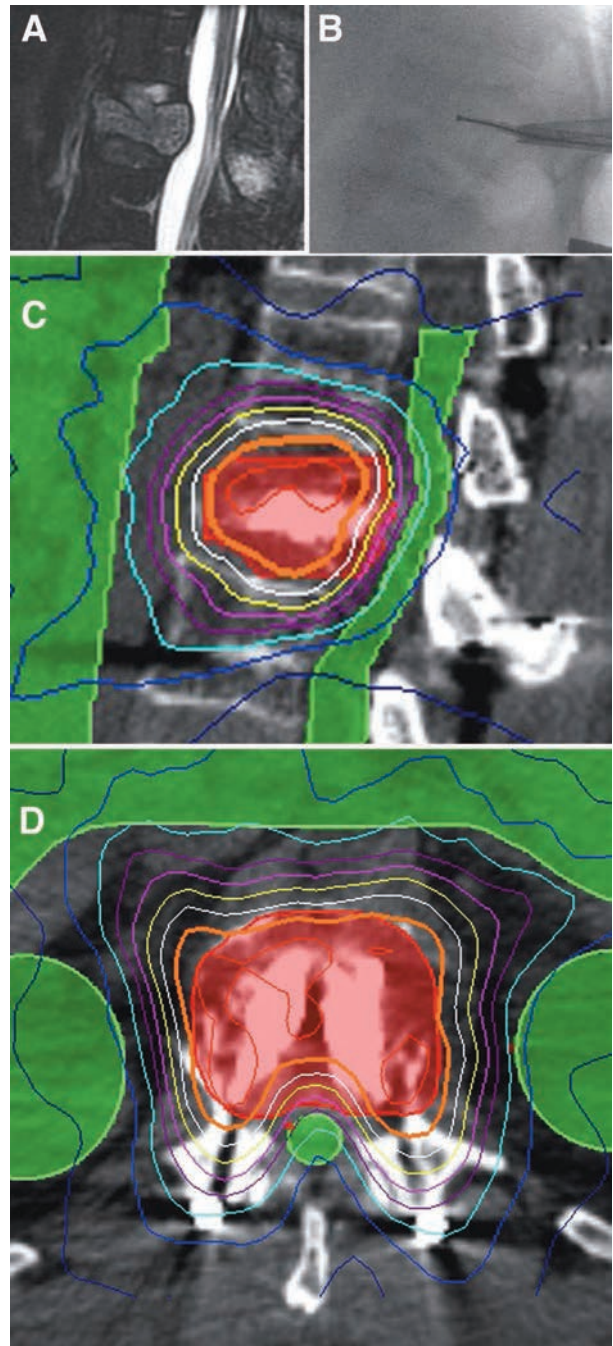


Fig. 2. Images obtained in a 74-year-old man with a symptomatic L-1 thyroid metastasis. A: Sagittal MR image showing the tumor. Note the degree of spinal canal compromise. B: Under fluoroscopic guidance, the device is inserted through an 8-gauge working channel and advanced in multiple directions to remove tumor tissue from within the vertebral body. C and D: Sagittal (C) and axial (D) projections of the isodose lines of the radiosurgical treatment plan demonstrating PMMA within the vertebral body.

The mean time interval between the surgery and radiosurgery procedures was 14 days (range 2–20 days). In no case did the patient undergo CT simulation on the same day as the surgical procedure due to the concern for incisional discomfort in the supine position.

The maximum prescribed tumor dose was main-

tained at 16–22.5 Gy contoured to the edge of the target volume (mean 19 Gy). The tumor volume ranged from 14.9 to 142.2 cm<sup>3</sup> (mean 51.3 cm<sup>3</sup>, median 37.2 cm<sup>3</sup>). This volume included the PMMA within the affected vertebral body in all cases. The single outlier of tumor volume of 142.2 cm<sup>3</sup> was a case of renal cell carcinoma at T-12 in which a large paraspinal tumor mass from T-11 to L-1 was included in the radiosurgical field. The mean dose delivered to the edge of the spinal cord was 9 Gy.

For evaluation of pain relief, a 10-point verbal visual analog scale with intensity description was administered prior to surgery, at 1 month after radiosurgery, and recorded through the last follow-up. The mean baseline pain score was 8. Ten of the 11 patients recorded at least some initial improvement in their pain after surgery and prior to radiosurgery. Long-term improvement in back pain as well as radiographic tumor control occurred in all 11 patients. The mean pain score at last follow-up evaluation was 3.

The follow-up for this patient cohort ranged from 7 to 44 months (mean 21 months, median 11 months). During a maximum follow-up period of 44 months, there were no clinically detectable neurological signs that could be attributable to acute or subacute radiation-induced spinal cord damage. The pain relief appeared to be durable in all cases at the last follow-up.

No acute radiation toxicity or new neurological deficit occurred during the follow-up period. Postoperative follow-up MR imaging revealed no changes suggestive of radiation-induced spinal cord injury in any case. Furthermore, no adjacent level compression fractures nor “out of field” tumor progression was demonstrated on MR imaging during the follow-up period. The barium-impregnated PMMA at the level of the treated tumor did not interfere with tracking of the fiducials or cone beam CT imaging during radiosurgical delivery. No patient later required open surgical stabilization for progressive kyphosis or mechanical instability. The angle of kyphotic deformity was not recorded before and after the procedures.

## Discussion

Metastatic spine tumors affect a large number of patients each year, resulting in significant pain, destruction of the spinal column causing mechanical instability, and neurological deficits.<sup>6,56,57</sup> Tumors are responsible for up to 10% of the estimated 750,000 vertebral compression fractures that occur annually in the US. Approximately 30% of cancer patients develop symptomatic spinal metastases during the course of their illness, and pain is the presenting complaint in most cases.<sup>10,17,53,54</sup> The spine is the third most common site in the body for cancer metastases. Vertebral tumors supplant bone in the vertebral body as they grow, resulting in a loss of structural integrity and ultimately fracture.

The emerging technique of using radiosurgery for spine metastases represents a logical extension of the current state-of-the-art radiation therapy. In recent years, advances in imaging technology, computerized treatment planning, and accurate dose delivery have allowed the safe delivery of spinal radiosurgery to spinal me-

tastases even in close proximity to the spinal cord and other paraspinal dose-sensitive organs. These treatments are often given in 1–5 fractions of high-dose radiation that are able to limit the dose to the spinal cord to safe doses.<sup>1,2,4,8,13,38,41,42,45,55</sup>

Radiosurgery has emerged as an important new treatment option in the multidisciplinary management of spine tumors.<sup>44</sup> The aims of radiosurgery are to improve on existing rates of clinical response and tumor control and to reduce the retreatment rate by increasing the biological equivalent dose.<sup>44</sup> With adequate long-term safety follow-up data, studies have determined that spinal radiosurgery is a safe and effective alternative to open surgery for a variety of both benign and malignant spinal tumors. Outcomes have focused on improvement in pain scores, safety, and improvement in both radiculopathy and myelopathy related to tumor compression.<sup>2,4,9,13,24,27,29,37,38,41–43,56</sup>

A relative reluctance for the wider adoption of bone cement augmentation for the treatment of pathological vertebral body fractures compared with benign osteoporotic fractures has been concerns related to higher procedural-related complications in this setting. In patients with osteolytic fractures, vertebroplasty is associated with an increased rate of cement leakage and less predictable pain relief.<sup>5</sup> To address such a complication and undesirable outcome associated with vertebroplasty, vertebral void creation using a balloon device is a means for controlled cement injection for pathological fractures secondary to spinal metastases. The kyphoplasty technique involves the insertion of a balloon into the vertebral body and the expansion of the balloon to displace bone and create a void. Cement is subsequently injected into the balloon-created void under fluoroscopic guidance and low pressure, which in turn theoretically reduces the risk of cement extravasation.<sup>17</sup> Lieberman and Reinhardt<sup>35</sup> and others have supported the kyphoplasty technique as a safer method.

As previously discussed, there are also several significant limitations of the kyphoplasty procedure for pathological compression fractures.<sup>15,17,30</sup> A reluctance to perform specifically the kyphoplasty procedure on tumor-related compression fractures has originated from 2 possible procedure-related risks. The first is the theoretical risk of embolizing tumor cells into the blood stream during balloon inflation. The second is the risk of retropulsion of the tumor mass during balloon inflation, leading to neurological consequences. In cases with posterior cortex disruption or cortical dissolution, this tissue migration can be difficult or impossible to observe fluoroscopically. These 2 factors are significant in evaluating the appropriateness of kyphoplasty as a treatment option for these patients, and have been stated as a relative contraindication by some authors.<sup>15,17,30</sup>

Techniques for creating a cavity by removing pathological tissue in a minimally invasive fashion prior to bone cement augmentation have been described.<sup>14,20,25</sup> The technique of combined coblation technology and percutaneous cement injection was first described by Percy and James.<sup>19</sup> A combined percutaneous vertebral body tumor debulking and bone cement augmentation technique offers the ability to improve the placement of

## Combined percutaneous corpectomy and radiosurgery technique

PMMA within the diseased vertebral body, potentially leading to increased safety as well as clinical effectiveness for stabilization of these fractures. The tumor removal achieved likely does not contribute to local tumor control, but rather is primarily for improved stabilization. Nevertheless, tumor removal from the vertebral body is not complete, and there is still a chance that there is a rim of tumor present between the PMMA and cortical bone. Many patients who are not believed to be candidates for vertebroplasty or kyphoplasty because of the extent of tumor causing significant canal compromise or the compromised integrity of the posterior wall of the vertebral body might now be candidates for PMMA placement. Open surgical decompression and stabilization might be avoided in even more patients with spinal metastases, affording these patients a less invasive approach to treating their condition.<sup>25</sup>

The direct decompressive resection for the treatment of spinal cord compression caused by metastatic cancer has been demonstrated in a randomized clinical trial and is now considered to be the standard of care compared with conventional radiotherapy alone.<sup>40</sup> In contrast to that study, the current series of patients did not have a neurological deficit from their spine metastases. None of these patients would have met the inclusion criteria for that trial. However, they did demonstrate at least some degree of spinal canal compromise that was believed to exclude them from safely performing balloon kyphoplasty.

In the currently described treatment paradigm, it is the radiosurgery component and not the tumor removal nor kyphoplasty procedure that provides for excellent local tumor control. There are several advantages to using a stereotactic radiosurgery technique as a primary treatment modality for spinal tumors instead of conventional fractionated radiotherapy after the percutaneous corpectomy technique.<sup>13</sup> Conformal radiosurgery avoids the need to irradiate large segments of the spinal cord. It may also avoid the need to irradiate large segments of the spinal column, known to have a deleterious effect on bone marrow reserve in these patients. Avoiding open surgery as well as preserving bone marrow function facilitates continuous chemotherapy in this patient population. Furthermore, improved local control, such as has been the case with intracranial radiosurgery, could translate into more effective palliation and potentially longer survival.

An advantage for the patient undergoing single-fraction radiosurgery is that the treatment can be completed in a single day rather than over the course of several weeks, which is not inconsequential for patients with a limited life expectancy. The technique may be useful to capitalize on possible advantages of radiosensitizers. In addition, cancer patients may have difficulty with access to a radiation treatment facility for prolonged, daily fractionated therapy. A large single fraction of irradiation may be more radiobiologically advantageous to certain tumors such as sarcomas, melanomas, and renal cell metastases compared with prolonged fractionated radiotherapy. Clinical response, such as pain or improvement of a neurological deficit, might also be more rapid with a radiosurgical technique. Finally, the procedure is mini-

mally invasive compared with open surgical techniques and can be performed in an outpatient setting.

Cardoso et al.<sup>7</sup> have described the interstitial delivery of samarium-153 coupled with kyphoplasty for the treatment of vertebral metastases. Similar to our technique, they demonstrated that the combined percutaneous debulking of confined vertebral metastases and the delivery of local radiotherapy for tumor control was feasible and safe. Radiosurgery may perhaps be a better modality for radiotherapy delivery because it avoids the requirement of mixing the samarium-153 with the PMMA and allows for a much larger biologically equivalent dose to be delivered not only to the vertebral body itself but also to paravertebral tumor if necessary.

The results obtained in this series demonstrate the safety and clinical effectiveness of percutaneous transpedicular corpectomy combined with cement augmentation followed by radiosurgery for symptomatic spine metastases with minimal to moderate spinal canal compromise. The goal of the treatment is to provide good palliative effect at the specific location of disease causing pain and associated disability. A combined percutaneous vertebral body tumor debulking and kyphoplasty technique offers the ability to improve the placement of PMMA within the affected vertebral body, potentially leading to increased safety as well as clinical effectiveness for stabilization of these fractures. Using radiosurgery, there is no reason to delay radiotherapy as is the case for conventional fractionated radiotherapy after open surgery. Our institution published a report on a series of 26 patients treated with radiosurgery after vertebral body cement augmentation,<sup>21</sup> in which the overall local control rate was 92%.

The technique described in this paper might serve an important new role in the minimally invasive treatment of patients with symptomatic spinal metastases with moderate spinal canal compromise. Subsequent radiosurgery provides for a highly conformal tumoricidal radiation dose to be delivered in a single session. The technique avoids the morbidity associated with open surgery while providing spinal canal decompression and immediate fracture stabilization as well as local tumor control.

### Disclosure

Dr. Gerszten serves as a consultant to ArthroCare, Inc.

### References

1. Amendola BE, Wolf AL, Coy SR, Amendola M, Bloch L: Gamma knife radiosurgery in the treatment of patients with single and multiple brain metastases from carcinoma of the breast. **Cancer J** 6:88–92, 2000
2. Benzil DL, Saboori M, Mogilner AY, Rocchio R, Moorthy CR: Safety and efficacy of stereotactic radiosurgery for tumors of the spine. **J Neurosurg** 101 (3 Suppl):413–418, 2004
3. Bilsky MH, Boakye M, Collignon F, Kraus D, Boland P: Operative management of metastatic and malignant primary subaxial cervical tumors. **J Neurosurg Spine** 2:256–264, 2005
4. Bilsky MH, Yamada Y, Yenice KM, Lovelock M, Hunt M, Gutin PH, et al: Intensity-modulated stereotactic radiotherapy of paraspinal tumors: a preliminary report. **Neurosurgery** 54: 823–831, 2004

5. Binning MJ, Gottfried ON, Klimo P Jr, Schmidt MH: Minimally invasive treatments for metastatic tumors of the spine. **Neurosurg Clin N Am** 15:459–465, 2004
6. Black P: Spinal metastasis: current status and recommended guidelines for management. **Neurosurgery** 5:726–746, 1979
7. Cardoso ER, Ashamalla H, Weng L, Mokhtar B, Ali S, Macedon M, et al: Percutaneous tumor curettage and interstitial delivery of samarium-153 coupled with kyphoplasty for treatment of vertebral metastases. **J Neurosurg Spine** 10:336–342, 2009
8. Chang EL, Shiu AS, Lii M-F, Rhines LD, Mendel E, Mahajan A, et al: Phase I clinical evaluation of near-simultaneous computed tomographic image-guided stereotactic body radiotherapy for spinal metastases. **Int J Radiat Oncol Biol Phys** 59:1288–1294, 2004
9. Chang SD, Adler JR Jr: Current status and optimal use of radiosurgery. **Oncology (Williston Park)** 15:209–221, 2001
10. Cobb CA III, Leavens ME, Eckles N: Indications for nonoperative treatment of spinal cord compression due to breast cancer. **J Neurosurg** 47:653–658, 1977
11. Cotten A, Boutry N, Cortet B, Assaker R, Demondion X, Leblond D, et al: Percutaneous vertebroplasty: state of the art. **Radiographics** 18:311–323, 1998
12. Deen HG, Fox TP: Balloon kyphoplasty for vertebral compression fractures secondary to polyostotic fibrous dysplasia. Case report. **J Neurosurg Spine** 3:234–237, 2005
13. Desalles AA, Pedrosa A, Medin P, Agazaryan N, Solberg T, Cabatan-Awang C, et al: Spinal lesions treated with Novalis shaped beam intensity modulated radiosurgery and stereotactic radiotherapy. **J Neurosurg** 101 (3 Suppl):435–440, 2004
14. Do H, Rippey M: Cancellous bone ablation with a plasma-mediated radiofrequency-based device: an in vivo study of temperature and gross effects in tissue, in **Congress of Neurological Surgeons**. Boston, 2005
15. Dudeney S, Lieberman IH, Reinhardt M-K, Hussein M: Kyphoplasty in the treatment of osteolytic vertebral compression fractures as a result of multiple myeloma. **J Clin Oncol** 20:2382–2387, 2002
16. Fessler R: Foreward. **Neurosurgery** 51:iii–iv, 2002
17. Fourney DR, Schomer DF, Nader R, Chlan-Fourney J, Suki D, Ahrar K, et al: Percutaneous vertebroplasty and kyphoplasty for painful vertebral body fractures in cancer patients. **J Neurosurg** (1 Suppl) 98:21–30, 2003
18. Gaitanis IN, Hadipavlou AG, Koatonis P, Tzermiadianos MN, Pasku DS, Patwardhan AG: Balloon kyphoplasty for the treatment of pathological vertebral compressive fractures. **Eur Spine Journal** 14:250–260, 2005
19. Georgy B, James B: Combined coblation technology and percutaneous cement injection in treatment of malignant vertebral lesions, in **American Society of Interventional Neuro-radiology**. Seattle, 2004
20. Georgy BA, Wong W: Plasma-mediated radiofrequency ablation assisted percutaneous cement injection for treating advanced malignant vertebral compression fractures. **AJNR Am J Neuroradiol** 28:700–705, 2007
21. Gerszten PC, Burton SA, Ozhasoglu C, Vogel WJ, Welch WC, Baar J, et al: Stereotactic radiosurgery for spinal metastases from renal cell carcinoma. **J Neurosurg Spine** 3:288–295, 2005
22. Gerszten PC, Germanwala A, Burton SA, Welch WC, Ozhasoglu C, Vogel WJ: Combination kyphoplasty and spinal radiosurgery: a new treatment paradigm for pathological fractures. **J Neurosurg Spine** 3:296–301, 2005
23. Gerszten PC, Ozhasoglu C, Burton S, Vogel WJ, Atkins BA, Kalnicki S, et al: CyberKnife frameless single-fraction stereotactic radiosurgery for benign tumors of the spine. **Neurosurg Focus** 14(5):1–5, 2003
24. Gerszten PC, Ozhasoglu C, Burton SA, Vogel WJ, Atkins BA, Kalnicki S, et al: CyberKnife frameless stereotactic radiosurgery for spinal lesions: clinical experience in 125 cases. **Neurosurgery** 55:89–99, 2004
25. Gerszten PC, Welch WC: Combined percutaneous transpedicular tumor debulking and kyphoplasty for pathological compression fractures. Technical note. **J Neurosurg Spine** 6:92–95, 2007
26. Gerszten PC, Welch WC: Current surgical management of metastatic spinal disease. **Oncology (Williston Park)** 14:1013–1024, 1029–1030, 2000
27. Gerszten PC, Welch WC: Cyberknife radiosurgery for metastatic spine tumors. **Neurosurg Clin N Am** 15:491–501, 2004
28. Halpin RJ, Bendok BR, Liu JC: Minimally invasive treatments for spinal metastases: vertebroplasty, kyphoplasty, and radiofrequency ablation. **J Support Oncol** 2:339–355, 2004
29. Hamilton AJ, Lulu BA, Fosmire H, Stea B, Cassidy JR: Preliminary clinical experience with linear accelerator-based spinal stereotactic radiosurgery. **Neurosurgery** 36:311–319, 1995
30. Hentschel SJ, Burton AW, Fourney DR, Rhines LD, Mendel E: Percutaneous vertebroplasty and kyphoplasty performed at a cancer center: refuting proposed contraindications. **J Neurosurg Spine** 2:436–440, 2005
31. Holman PJ, Suki D, McCutcheon I, Wolinsky JP, Rhines LD, Gokaslan ZL: Surgical management of metastatic disease of the lumbar spine: experience with 139 patients. **J Neurosurg Spine** 2:550–563, 2005
32. Horn EM, Henn JS, Lemole GM Jr, Hott JS, Dickman CA: Thoracoscopic placement of dual-rod instrumentation in thoracic spinal trauma. **Neurosurgery** 54:1150–1154, 2004
33. Karasek M, Bogduk N: Twelve-month follow-up of a controlled trial of intradiscal thermal anuloplasty for back pain due to intervertebral disc disruption. **Spine (Phila Pa 1976)** 25:2601–2607, 2000
34. Ledlie J, Renfro M: Balloon kyphoplasty: one-year outcomes in vertebral body height restoration, chronic pain and activity levels. **J Neurosurg** 98 (1 Suppl):36–42, 2003
35. Lieberman I, Reinhardt MK: Vertebroplasty and kyphoplasty for osteolytic vertebral collapse. **Clin Orthop Relat Res** (415 Suppl):S176–S186, 2003
36. Lieberman IH, Dudeney S, Reinhardt MK, Bell G: Initial outcome and efficacy of “kyphoplasty” in the treatment of painful osteoporotic vertebral compression fractures. **Spine (Phila Pa 1976)** 26:1631–1638, 2001
37. Medin PM, Solberg TD, De Salles AA, Cagnon CH, Selch MT, Johnson JP, et al: Investigations of a minimally invasive method for treatment of spinal malignancies with LINAC stereotactic radiation therapy: accuracy and animal studies. **Int J Radiat Oncol Biol Phys** 52:1111–1122, 2002
38. Milker-Zabel S, Zabel A, Thilmann C, Schlegel W, Wannemacher M, Debus J: Clinical results of retreatment of vertebral bone metastases by stereotactic conformal radiotherapy and intensity-modulated radiotherapy. **Int J Radiat Oncol Biol Phys** 55:162–167, 2003
39. North RB, LaRocca VR, Schwartz J, North CA, Zahurak M, Davis RF, et al: Surgical management of spinal metastases: analysis of prognostic factors during a 10-year experience. **J Neurosurg Spine** 2:564–573, 2005
40. Patchell RA, Tibbs PA, Regine WF, Payne R, Saris S, Kryscio RJ, et al: Direct decompressive surgical resection in the treatment of spinal cord compression caused by metastatic cancer: a randomised trial. **The Lancet** 366:643–648, 2005
41. Ryu SI, Chang SD, Kim DH, Murphy MJ, Le QT, Martin DP, et al: Image-guided hypo-fractionated stereotactic radiosurgery to spinal lesions. **Neurosurgery** 49:838–846, 2001
42. Ryu S, Fang Yin F, Rock J, Zhu J, Chu A, Kagan E, et al: Image-guided and intensity-modulated radiosurgery for patients with spinal metastasis. **Cancer** 97:2013–2018, 2003
43. Ryu S, Rock J, Rosenblum M, Kim JH: Patterns of failure after

## Combined percutaneous corpectomy and radiosurgery technique

- single-dose radiosurgery for spinal metastasis. **J Neurosurg** **101** (3 Suppl):402–405, 2004
44. Sahgal A, Ames C, Chou D, Huang K, Xu W, Chin C, et al: Stereotactic body radiotherapy is effective salvage therapy for patients with prior radiation of spinal metastases. **Int J Radiat Oncol Biol Phys** **74**:723–731, 2009
45. Shiu AS, Chang EL, Ye J-S, Lii M, Rhines LD, Mendel E, et al: Near simultaneous computed tomography image-guided stereotactic spinal radiotherapy: an emerging paradigm for achieving true stereotaxy. **Int J Radiat Oncol Biol Phys** **57**:605–613, 2003
46. Singh K, Samartzis D, Vaccaro AR, Andersson GB, An HS, Heller JG: Current concepts in the management of metastatic spinal disease. The role of minimally-invasive approaches. **J Bone Joint Surg Br** **88**:434–442, 2006
47. Song DY, Kavanagh BD, Benedict SH, Schefter T: Stereotactic body radiation therapy. Rationale, techniques, applications, and optimization. **Oncology (Williston Park)** **18**:1419–1430, 1432, 1435–1436, 2004
48. Togawa D, Lieberman IH, Bauer TW, Reinhardt MK, Kayanja MM: Histological evaluation of biopsies obtained from vertebral compression fractures: unsuspected myeloma and osteomalacia. **Spine (Phila Pa 1976)** **30**:781–786, 2005
49. Vitaz T, Oishi M, Welch W, Gerszten PC, Disa JJ, Bilsky MH: Rotational and transpositional flaps for the treatment of spinal wound dehiscence and infections in patient populations with degenerative and oncological disease. **J Neurosurg** (1 Suppl) **100**:46–51, 2004
50. Wang JC, Boland P, Mitra N, Yamada Y, Lis E, Stubblefield M, et al: Single-stage posterolateral transpedicular approach for resection of epidural metastatic spine tumors involving the vertebral body with circumferential reconstruction: results in 140 patients. Invited submission from the Joint Section Meeting on Disorders of the Spine and Peripheral Nerves, March 2004. **J Neurosurg** (1 Suppl):287–298, 2004
51. Weigel B, Maghsudi M, Neumann C, Kretschmer R, Müller FJ, Nerlich M: Surgical management of symptomatic spinal metastases. Postoperative outcome and quality of life. **Spine (Phila Pa 1976)** **24**:2240–2246, 1999
52. Weill A, Chiras J, Simon JM, Rose M, Sola-Martinez T, Enkaoua E: Spinal metastases: indications for and results of percutaneous injection of acrylic surgical cement. **Radiology** **199**:241–247, 1996
53. Wong DA, Fornasier VL, MacNab I: Spinal metastases: the obvious, the occult, and the impostors. **Spine (Phila Pa 1976)** **15**:1–4, 1990
54. Wong W, Reiley MA, Garfin S: Vertebroplasty/kyphoplasty. **J Women's Imag** **2**:117–124, 2000
55. Yamada Y, Lovelock DM, Bilsky MH: A review of image-guided intensity-modulated radiotherapy for spinal tumors. **Neurosurgery** **61**:226–235, 2007
56. Yin FF, Ryu S, Ajlouni M, Yan H, Jin JY, Lee SW, et al: Image-guided procedures for intensity-modulated spinal radiosurgery. Technical note. **J Neurosurg** **101** (Suppl 3):419–424, 2004
57. Young JM, Funk FJ Jr: Incidence of tumor metastasis to the lumbar spine; a comparative study of roentgenographic changes and gross lesions. **J Bone Joint Surg Am** **35-A**:55–64, 1953

Manuscript submitted August 6, 2009.

Accepted September 3, 2009.

*Address correspondence to:* Peter C. Gerszten, M.D., M.P.H., Department of Neurological Surgery, Presbyterian University Hospital, Suite B-400, 200 Lothrop Street, Pittsburgh, Pennsylvania 15213. email: gersztenpc@upmc.edu.